

The radiological investigation of suspected physical abuse in children

Contents

Foreword	3
1. Introduction	4
2. Recommendations	5
References	11
3. Evidence base	12
4. Working party members and other contributors	20
Appendix A. Skeletal survey: standard views, including follow up, to be obtained	21
Appendix B. Exemplar information leaflet for those with parental responsibility	23
Appendix C. Exemplar consent form	27
Appendix D. Exemplar skeletal survey competency form	30
Appendix E. Exemplar initial skeletal survey check form	35
Appendix F. Alternative forms of skeletal imaging	40
Appendix G. Exemplar follow-up imaging form for those with parental responsibility	42
Appendix H. Exemplar follow-up imaging form for those with parental responsibility	43
Appendix I. Exemplar standard operating procedure for follow-up imaging	46
Appendix J. Neuro imaging algorithm for suspected physical abuse	51
Appendix K. MRI protocols	52
Appendix L. Audit proforma	53

A joint publication from The Royal College of Radiologists
and The Society and College of Radiographers

Endorsed by the Royal College of Paediatrics and Child Health



Foreword

This new guidance supersedes the 2008 document by The Royal College of Radiologists (RCR) and Royal College of Paediatrics and Child Health (RCPCH) *Standards for radiological investigations of suspected non-accidental injury*. The previous document, which was based on the latest guidance and recommendations then available, was very well received and helped healthcare professionals to image children with suspected non-accidental injury.

This new guidance is the result of collaboration between the RCR and the Society and College of Radiographers (SCoR) and is endorsed by the RCPCH. It has also involved considerable input from members of the RCPCH, the Association of Paediatric Radiographers and the International Association of Forensic Radiographers.

The RCR and SCoR are very grateful to Dr Kath Halliday, who chaired the working party which revised this guidance, all members of the working party who contributed their time and expertise and other colleagues who contributed to the process.

As with all RCR documents, this will be kept under review to ensure that it remains up to date.

Dr Richard FitzGerald
Vice-President, Faculty of Clinical
Radiology
The Royal College of Radiologists

Steve Herring BSc (Hons) (R) PgD
President Society and College of
Radiographers

1. Introduction

The original document, *Standards for radiological investigations of suspected non-accidental injury*, was published jointly in 2008 by The Royal College of Radiologists (RCR) and the Royal College of Paediatrics and Child Health (RCPCH). The document stressed that child protection should be everyone's responsibility and highlighted the particular responsibilities of paediatricians and radiologists in such cases. The standards were adopted throughout the UK and formally adopted by the European Society of Paediatric Radiologists.

Following discussions with partner organisations, this updated version has been produced jointly with the Society and College of Radiographers and endorsed by the RCPCH and has involved extensive contributions from representatives of the RCPCH. The objective of the working party which led this work was to revise the document to ensure that it remains up to date and fit for purpose.

We have identified the imaging that should be undertaken when physical abuse of a child is suspected. The majority of such cases will involve children under two years old. Older children should be considered on a case-by-case basis. This guidance is designed to assist referring clinicians, paediatricians, radiologists, radiographers and nuclear medicine technologists who are requesting, performing or reporting on imaging in such cases by taking them through the process in a logical and structured manner, setting out clear recommendations for each stage and providing exemplar forms and documentation.

Throughout the document, use of the word 'must' indicates a necessary action or behaviour. Use of the word 'should' indicates actions or behaviours which are expected to occur in normal circumstances. The word 'may' is used to indicate a discretionary action which might or might not be appropriate depending on professional judgement.

In producing this guidance, the key questions we have addressed are:

- Which children should be imaged when physical abuse is suspected?
- Which imaging modalities should be used to maximise detection of occult injuries, while limiting unnecessary radiation exposure?
- How should the imaging be performed, reported and communicated?
- When should initial and follow-up imaging be undertaken?

At all times, the comfort and safety of the child is of the utmost importance.

In developing this guidance, we have sought to incorporate evidence-based changes for the type of imaging conducted to detect occult injuries, while minimising radiation exposure and patient distress. Evidence has been considered, reviewed and discussed extensively by the working party and other experts and informal consensus reached, based on the professional judgements of those involved. A full report of the methodology involved in the production of this guidance is available on the RCR website (www.rcr.ac.uk/suspected-physical-abuse/methodology).

The working party was conscious of the need to avoid imposing unnecessary burdens on the service. While there may be some potential staffing implications arising from the recommendations, the working party believes these will be offset by the resulting rationalisation of processes and the saving in staff time and effort that this will achieve and has provided exemplar forms to assist services.

In addition, the potential barrier of a lack of specialist paediatric imaging expertise can be addressed through regional radiological and radiographic networks. The RCR set out its vision for networks of expertise and, in December 2016, published *Who Shares Wins: efficient, collaborative radiology solutions*, which explains what imaging departments should demand from radiology information system (RIS) and picture archiving and communication system (PACS) vendors to ensure that their radiology information technology can support the sharing of images and networking through systems that interact seamlessly regardless of vendor.^{1,2}

We hope that our recommendations help those involved in the care and imaging of such cases to understand and maintain the high levels of service required when concerns about the health and wellbeing of children are being investigated.

2. Recommendations

Decisions about suspected physical abuse

A senior clinician (usually a paediatrician) who suspects that a child has been subjected to physical abuse will need to request medical imaging to identify injury. Material and information to assist with decisions concerning suspected physical abuse are included in the RCPCH's Child Protection Companion.³

What imaging is required?

1. Imaging should always include skeletal survey in children under two years old and skeletal survey and computed tomography (CT) head scan in children under one year old. See Appendix A for the standards views to be obtained.
2. Children who are older than one year and have external evidence of head trauma and/or abnormal neurological symptoms or signs should also have a CT head scan.
3. Skeletal survey may occasionally be indicated in older children; this should be considered on a case-by-case basis.

This may include children with communication or learning difficulties or neurodisability who may be unable to give a history of physical abuse or children where there is a clinical suspicion of skeletal injury.

4. Where a child is suspected of being the victim of physical abuse, the following children under two years old should also undergo imaging regardless of the findings from any physical examinations:
 - Any multiple birth sibling such as a twin, triplet or quad
 - Siblings and children living in the same household or family.
5. Children who have been abused may suffer other forms of injury including trauma to the chest and abdomen. The investigation of suspected abdominal and thoracic injuries in suspected physical abuse should be no different from the imaging used for accidental trauma and body CT is the imaging modality of choice.
6. Although it has been shown that CT has a greater sensitivity than radiography for the detection of rib (vertebral and scapular) fractures, there is currently insufficient evidence regarding which patients would benefit or the concurrent role of 3/4 view chest radiography. Consider chest CT when abuse is suspected and there is doubt regarding the nature of rib abnormality identified on chest radiograph(s).

Referral to social care and the safeguarding team

7. Where a child has a clear indication for radiological imaging and these guidelines are not followed, the reasons for non-adherence should be recorded in the patient's notes by the senior clinician.
8. When physical abuse is suspected, a referral to social care must be made as soon as possible and always within 24 hours.
9. Any healthcare professional who continues to have concerns regarding the safety of a child, despite assurances from the referring clinician that a referral to social care is not required, should seek advice from the safeguarding team within their authority and discuss their concerns with the named or designated doctor.

Requesting imaging

10. Complete clinical information must be provided with the request which will be justified by the radiologist.⁴
11. The referring clinician should provide a clear explanation to the person with parental responsibility of the reasons for the imaging requested, including the procedure and the risks. An explanatory leaflet should be provided.

An exemplar leaflet for those with parental responsibility is included as Appendix B. Before this is used, professionals should ensure that it complies with the local healthcare provider's protocols and make any necessary amendments.

12. Written consent from a person with parental responsibility should be obtained by the referring clinician for all imaging of suspected physical abuse investigations, unless there are overriding circumstances of clinical urgency. If consent is declined then an application should be made for a court order for the procedure to be undertaken because the health and well being of the child is paramount.

An exemplar consent form is included as Appendix C. Before this is used, professionals should ensure that it complies with the local healthcare provider's protocols and make any necessary amendments.

13. The consent of those individuals with parental responsibility should be verbally reaffirmed by the examining radiographers. Should consent be withdrawn during the radiological examination, the examination should be stopped immediately and the case referred back to the consultant paediatrician.

The exemplar consent form included as Appendix C covers the points of consent that the radiographer needs to reaffirm. Where a person with parental responsibility declines to attend the department for the imaging examination and the child is accompanied by a member of the professional nursing team, the radiographer should satisfy themselves that appropriate consent of the person with parental responsibility has been given for the examination to go ahead in their absence, for example, additional annotation on the original consent document, annotation in the child's care record clearly identifying the person with parental responsibility is aware of the examination and has consented to it in their absence or a documented direct conversation by the radiographer with that person prior to the examination.

The skeletal survey

14. The skeletal survey should be acquired and reported, within 24 hours and certainly no later than 72 hours from the request being made.

While it is essential that imaging is performed and reported by staff with appropriate training and experience, it is unacceptable for children and families to wait more than three days for investigations which are so crucial to their future. In the event that appropriately trained staff are not available, imaging networks should be established.

15. Two radiographers with documented education and training in paediatric and forensic radiography techniques should perform the skeletal survey.

Details of approved training can be found on the Society and College of Radiographers' website.^{5,6} An exemplar form for recording skeletal survey competency is included as Appendix D. Before this is used, professionals should ensure that it complies with the local healthcare provider's protocols and make any necessary amendments.

16. In the event that appropriately trained radiographers and radiologists are not available in the admitting hospital, robust arrangements should be in place to access appropriate expertise at other hospitals within a suitable time frame, no later than 72 hours from the request being made.

17. Correct identification of the child by both radiographers involved in performing the skeletal survey should be confirmed and documented at the time of examination.

18. In addition to the radiographers, a registered paediatric nurse or a registered health or care practitioner should be present during the examination. This should be a statutorily regulated healthcare professional who a) is able to act autonomously and b) has a scope of practice which includes an understanding of the legislation applying to children with suspected physical abuse. Examples of appropriate staff roles include registered paediatric nurse or registered nurse with paediatric training. The roles of healthcare assistant, assistant practitioner and associate professional do not currently meet the criteria of statutory regulation.

19. If individuals with parental responsibility wish to be present, and there are no concerns regarding the immediate safety of the child, this should be encouraged.

20. Skeletal surveys should be undertaken in a child friendly environment within a radiology department that is equipped for paediatric imaging.

21. Effective immobilisation is essential to obtain good quality images. This usually involves the child being held by an adult. Where a person with parental responsibility is unable to assist, another member of staff may do so. Anyone who holds a child should be informed about how they can assist. Records must be kept for all those who assist during exposures and audited to ensure that the same person is not routinely asked to assist.

22. The skeletal survey can be a distressing examination for children, family and staff. Sedation of a child may be helpful and, where appropriate, local policies should be followed.

23. In the event that sedation is not used, appropriate distraction toys should be available. Involvement of play therapists should be considered.

24. Anatomical side markers should be present within the primary beam, but not overlying any body parts. Where an image is satisfactory, except for the visibility of anatomical markers, imaging staff should consider whether a repeat exposure is necessary. Where it is absolutely clear that right and left can be identified there is normally no need for repeat imaging. Decisions regarding this should be documented in the clinical record.

All annotations, including 'left' and 'right' markers added after image acquisition, should be recorded within the examination document, see the exemplar initial skeletal survey check form at Appendix E. Before this is used, professionals should ensure that it complies with the local healthcare provider's protocols and make any necessary amendments.

25. A standard set of views should be obtained, see Appendix A.

26. Appropriate documentation and contemporaneous records should be maintained, see Appendix E.

27. Skeletal surveys should be reviewed by a radiologist with experience of reporting such studies within 24 hours in case repeat or additional views are needed.

Reporting

28. Two radiologists with at least six months of specialist paediatric radiology training, including experience of suspected physical abuse in children, should provide a consensus report within 24 hours.

29. All clinical reports should adhere to the RCR Standards for the reporting and interpretation of imaging investigations.⁷ The report(s) should be acknowledged by the referring clinician in the child's permanent medical record.

30. Findings from the imaging investigations should be actively communicated to the requesting clinician in a timely manner and meet the requirements of their employer's fail-safe alert notification system.

31. There should be a robust and reliable method for the referrer to discuss cases with the reporter, for example, at the multidisciplinary team meeting (MDTMs).

Additional and alternative imaging

32. In cases where there is diagnostic uncertainty in relation to skeletal injury, a request for additional imaging, including alternative modalities, should be considered.

See Appendix F in relation to alternative forms of skeletal imaging: CT, ultrasound (US), bone scanning or magnetic resonance imaging (MRI).

Follow-up imaging

33. Follow-up imaging should be performed ideally within 11 to 14 days, and no later than 28 days after the initial skeletal survey.

Even if the initial skeletal survey is normal, all children should have follow-up imaging. This is because follow-up imaging may identify fractures which only become visible when healing. It also provides invaluable information about fractures identified or suspected on the initial imaging and can assist with dating the injuries.

Follow-up imaging should include the views set out in Appendix A. An exemplar follow-up imaging form for those with parental responsibility is attached as Appendix G, together with an exemplar follow-up skeletal survey check form, see Appendix H. Before these are used, professionals should ensure that they comply with the local healthcare provider's protocols and make any necessary amendments.

34. Robust procedures should be put in place and documented to ensure that all patients return for follow-up imaging. A named professional should be identified to ensure that follow-up imaging is obtained and to follow up missed appointments if necessary.

An exemplar standard operating procedure has been included as Appendix I. Before this is used, professionals should ensure that it complies with the local healthcare provider's protocols and make any necessary amendments.

Neurological imaging

35. Unenhanced cranial CT scanning should be performed from immediately below the skull base to above the vertex as soon as the patient is stable on the day of admission. All cranial CT scanning should be undertaken using a multi-slice technique, with a thickness of 0.8 mm and routine 3D surface reconstructed images generated and stored at the time of the scan, see Appendix J.

NB: Recommendation 16 also applies to cross-sectional imaging modalities. 3D surface reconstructed images employing bone and soft tissue windows should be undertaken for better appreciation of skull fractures and associated scalp soft tissue injuries.

36. Multiplanar reconstructions should be made in true coronal and true sagittal planes.
37. MRI of the head should be performed at day 2–5 for all children when CT has demonstrated intracranial haemorrhage and/or parenchymal brain injury and/or skull fracture.
38. MRI of the head should also be performed at day 2–5, for children in who there are ongoing abnormal neurological symptoms or signs irrespective of an apparently normal initial CT scan see Appendix J.
39. Any child that has had an MRI of the head in this context should also have an MRI of the whole spine at the same time.
40. In children who are older than one year, some injuries have a high association with abusive head trauma such as rib fracture, spinal fracture, retinal haemorrhage and visceral trauma. In such cases that present acutely, CT imaging of the head should be considered.
41. CT and MR scans should be reported by a radiologist with appropriate expertise in paediatric neurological imaging. If such expertise is not available in an acute situation, the imaging should be reviewed at the earliest possible opportunity by a radiologist with the specified expertise.
42. Craniospinal MRI should be undertaken at field strengths between 1.5T and 3T with appropriate surface coils for imaging infants and by nursing, radiographic and anaesthetic personnel experienced in imaging very young children. See Appendix K for recommended MRI protocols.

43. Further follow-up MRI of the head may be indicated. See Appendix J for timetable for neurological imaging and Appendix K for recommended protocols.

The rationale for follow-up MRI is to identify evolving brain damage which may have long-term developmental consequences and for which the early institution of rehabilitation and support would be beneficial; and to further inform any ongoing legal proceedings and potential criminal injuries compensation cases.

44. Where abuse is historic, a child may present with:

- Unexplained neurological abnormalities
- Neurological developmental concerns in the context of suspected physical abuse
- An unexplained increasing head circumference.

In such cases, MRI of the head is the best firstline imaging investigation and should be performed urgently in view of child protection concerns for the individual child and for their siblings.

Standard MRI protocols should be obtained as suggested in Appendix K, but in these cases, spinal imaging is not required routinely.

Any CT or MR imaging should be acquired and reported, within 24 hours and certainly no later than 72 hours from the request being made.

The deceased child

45. Post-mortem imaging of the whole body, including the brain, is indicated in all cases of sudden unexpected death in infancy (SUDI). The most extreme outcome from suspected child abuse is fatal injury. In the post-mortem setting, the procedure should be the same as in life, that is, full skeletal survey and neuroimaging as appropriate using the above guidelines, with cross-sectional imaging recommended in suspected thoracic or abdominal trauma. In particular, in sudden unexpected death in infancy, whole-body CT should be used to investigate skeletal injuries or if there is diagnostic doubt on the skeletal survey. Post-mortem MRI of the whole body should be used if there is suspected soft tissue injury.

Approved by the Board of the Faculty of Clinical Radiology: 23 June 2017

Approved by Council of the Society and College of Radiographers: 10 May 2017

References

1. The Royal College of Radiologists. *Dalton Review – RCR Clinical Radiology Proposal: Radiology in the UK – the case for a new service model*. London 2014: The Royal College of Radiologists.
 2. The Royal College of Radiologists. *Who shares wins: efficient, collaborative radiology solutions*. London: The Royal College of Radiologists, 2016.
 3. www.pcouk.org/ (last accessed 11/8/17) (subscription required)
 4. UK Government. *The Ionising Radiation (Medical Exposure) Regulations 2000*. London: The Stationery Office, 2000.
 5. Society and College of Radiographers. *Practice standards for the imaging of children and young people*. London: Society and College of Radiographers, 2009.
 6. Society and College of Radiographers. *Guidance for radiographers providing forensic radiography services*. London: The Royal College of Radiographers, 2014.
 7. The Royal College of Radiologists. *Standards for the reporting and interpretation of imaging investigations*. London: The Royal College of Radiologists, 2006.
-

3. Evidence base

Decisions about suspected physical abuse

1. RCPCH Child Protection Companion at <http://pcouk.org/> (requires Paediatric Care Online subscription – last accessed 16/8/2017).
2. HM Government. *What to do if you're worried a child is being abused: advice for practitioners*. London: HM Government, 2015.
3. HM Government. *Working together to safeguard children: a guide to inter-agency working to safeguard and promote the welfare of children*. London: HM Government, 2015.
4. National Institute for Health and Care Excellence. Child maltreatment: when to suspect maltreatment in under 18s: Clinical guideline. London: National Institute for Health and Care Excellence.

Recommendation 1

5. Harper NS, Feldman KW, Sugar NF *et al*. Additional injuries in your infants with concern for abuse and apparently isolated bruises. *J Pediatr* 2014; **165**(2): 383–388.
6. Laskey AL, Holsti M, Runyan DK, Socolar RR. Occult head trauma in young suspected victims of physical abuse. *J Pediatr* 2004; **144**(6): 719–722.
7. Rubin DM, Christian CW, Bilaniuk LT, Zazyczny KA, Durbin DR. Occult head injury in high risk abused children. *Paediatrics* 2003; **111**(6Pt1): 1,382–1386.
8. Greenes DS, Schutzman SA. Occult intracranial injury in infants. *Ann Emerg Med* 1998; **32**(6): 680–686.

Recommendation 2

9. National Institute for Health and Care Excellence. *Head injury: assessment and early management*. London: National Institute for Health and Care Excellence, 2014.
10. Kemp AM, Rajaram S, Mann M *et al*. What neuroimaging should be performed in children in whom inflicted brain injury (IBI) is suspected? A systematic review. *Clin Radiol* 2009; **64**(5): 473–483.

Recommendation 4

11. Day F, Clegg S, McPhillips M, Mok J. A retrospective case series of skeletal surveys in children with suspected non-accidental injury. *J Clin Forensic Med* 2006; **13**(2): 55–59.
12. Lang CA, Cox MJ, Flores G. Maltreatment in multiple birth children. *Child Abuse Negl* 2013; **37**(12): 1109–1113.
13. Lindberg DM, Blood EA, Campbell KA *et al*. Predictors of screening and injury in contacts of physically abused children. *J Pediatr* 2013; **163**(3): 730–735.
14. Lindberg DM, Shapiro RA, Laskey AL *et al*. Prevalence of abusive injuries in siblings and household contacts of physically abused children. *Paediatrics* 2012; **130**(2): 193–201.
15. Lindberg DM, Berger RP, Reynolds MS *et al*. Yield of skeletal survey by age in children referred to abuse specialists. *J Pediatr* 2014; **164**(6): 1268–1273.

Recommendation 5

16. The Royal College of Radiologists. Paediatric trauma protocols. London 2014: The Royal College of Radiologists, 2014.

17. Hilmes MA, Hernanz-Schulman M, Greeley CS, Piercey LM, Yu C, Kan JH. CT identification of abdominal injuries in abused pre-school-age children. *Paediatr Radiol* 2011; **41**(5): 643–51.

Recommendation 6

18. Hong TS, Reyes JA, Moineddin R *et al.* Value of post-mortem thoracic CT over radiography in imaging of pediatric rib fractures. *Pediatr Radiol* 2011; **41**(6): 736–748.
19. Wootton-Gorges SL, Stein-Wexler R, Walton JW *et al.* Comparison of computed tomography and chest radiography in the detection of rib fractures in abused infants. *Child Abuse Negl* 2008; **32**(6): 659–663.
20. Sanchez TR, Lee JS, Coulter KP, Seibert JA, Stein-Wexler R. CT of the chest in suspected child abuse using submillisievert radiation dose. *Pediatr Radiol* 2015; **45**(7): 1072–1076.

Recommendation 7

21. Royal College of Paediatrics and Child Health. *Safeguarding children and young people: roles and competencies for health care staff, intercollegiate document*. London: The Royal College of Paediatrics and Child Health 2014.
22. The Health and Care Professions Council. *Standards of proficiency (Radiographers)*. London: The Health and Care Professions Council, 2013.
23. General Medical Council. *Protecting children and young people: the responsibilities of all doctors*. Manchester: General Medical Council, 2012.
24. The Department of Health. *Getting the right start: national service framework for children*. London: Department of Health, 2003.
25. Baroness Kennedy QC. *Sudden unexpected death in infancy: multi-agency guidelines for care and investigation, second edition*. London: The Royal College of Pathologists and The Royal College of Paediatrics and Child Health, 2016.
26. H M Government. *Working together to safeguard children*. London: H M Government, 2015.

Recommendation 8

27. Royal College of Paediatrics and Child Health Child Protection Companion at <http://pcouk.org/> (requires Paediatric Care Online subscription – last accessed 16/8/2017).

Recommendation 9

28. General Medical Council. *Raising and acting on concerns about patient safety*. London: General Medical Council, 2012.
29. H M Government. *Every child matters*. London: The Stationery Office, 2003.
30. Society and College of Radiographers. *Raising concerns in the workplace*. London: Society and College of Radiographers, 2015.
31. Health & Care Professions Council. *HCPC response to the report of the Freedom to Speak Up Review*. London: Heath & Care Professions Council, 2015.

Recommendation 10

- 32. www.gmc-uk.org/guidance/good_medical_practice/continuity_care.asp (last accessed 16/8/2017)
- 33. www.legislation.gov.uk/ukxi/2000/1059/regulation/6/made (last accessed 17/8/2017)

Recommendation 12

- 34. General Medical Council. *Consent: patients and doctors making decisions together*. London: General Medical Council, 2008.
- 35. Society and College of Radiographers. *The child and the law: roles and responsibilities of the radiographer*. London: Society and College of Radiographers, 2005.
- 36. Society and College of Radiographers. *Skeletal surveys for suspected NAI, SIDS and SUDI: guidance for radiographers*. London: Society and College of Radiographers, 2009.
- 37. Society and College of Radiographers. *Guidance for radiographers providing forensic radiography services*. London: Society and College of Radiographers, 2014.
- 38. Scheurer E, Schoelzke S. Consent to forensic radiological examinations by living crime victims. *Int J Legal Med* 2014; **128**(2): 323–328.

Recommendation 13

- 39. Society and College of Radiographers. *The child and the law: roles and responsibilities of the radiographer*. London: Society and College of Radiographers, 2005.
- 40. Society and College of Radiographers. *Skeletal surveys for suspected NAI, SIDS and SUDI: guidance for radiographers*. London: Society and College of Radiographers, 2009

Recommendation 14

- 41. National Imaging Board. *Delivering quality imaging services for children*. London: National Imaging Board, 2010.

Recommendation 15

- 42. Society and College of Radiographers. *Standards of radiographic practice for post-mortem cross-sectional imaging (PMC-SI)*. London: Society and College of Radiographers, 2015.
- 43. Society and College of Radiographers. *Skeletal surveys for suspected NAI, SIDS and SUDI: guidance for radiographers*. London: Society and College of Radiographers, 2009
- 44. Glaysher E, Vallis J, Reeves P. Post traumatic stress disorder and the forensic radiographer. *Radiography online* 2016; **22**(3) e212–215.
- 45. Society and College of Radiographers. *Guidance for radiographers providing forensic radiography services*. London: Society and College of Radiographers, 2014.
- 46. Society and College of Radiographers. *Practice standards for the imaging of children and young people*. London: Society and College of Radiographers, 2009

Recommendation 16

- 47. National Imaging Board. *Delivering quality imaging services for children*. London: National Imaging Board, 2010.

Recommendation 17

48. Society and College of Radiographers. *Guidance for radiographers providing forensic radiography services*. London: Society and College of Radiographers, 2014.
49. Society and College of Radiographers. *Skeletal surveys for suspected NAI, SIDS and SUDI: guidance for radiographers*. London: Society and College of Radiographers, 2009.
50. The Health and Care Professions Council. *Standards of proficiency (Radiographers)*. London: The Health and Care Professions Council, 2013.
51. Clinical Imaging Board. *Patient identification: guidance and advice*. London: Clinical Imaging Board, 2016.

Recommendation 18

52. Society and College of Radiographers. *Skeletal surveys for suspected NAI, SIDS and SUDI: guidance for radiographers*. London: Society and College of Radiographers, 2009.

Recommendation 19

53. United Nations Human Rights Office of the High Commission. *Article 9 in Convention on the rights of the child*. Geneva, United Nations Human Rights Office of the High Commission, 1989.
54. Society and College of Radiographers. *Imaging children: immobilisation, distraction techniques and use of sedation*. London: Society and College of Radiographers, 2012.
55. Society and College of Radiographers. *The Ionising Radiations Regulations 1999 (IRR'99): guidance booklet*. London: Society and College of Radiographers, 2012.
56. Society and College of Radiographers. *The child and the law: roles and responsibilities of the radiographer*. London: Society and College of Radiographers, 2005.
57. Hardy M and Boynes S. *Paediatric radiography*. London: Wiley-Blackwell, 2003.
58. Graham P, Hardy M. The immobilisation and restraint of paediatric patients during plain film radiographic examinations. *Radiography* 2004; **10**(1): 23–31.
59. Royal College of Nursing. *Restrictive physical intervention and therapeutic holding for children and young people*. London: Royal College of Nursing, 2010.

Recommendation 20

60. European Association for Children in Hospital. *Article 8 in The EACH Charter*. European Association for Children in Hospital, 1988.
61. H M Government. *Children and families act 2014*. London: The Stationery Office, 2014.
62. H M Government. *Children and young persons act 2008*. London: The Stationery Office, 2008.
63. H M Government. *Working together to safeguard children*. London: H M Government, 2015.
64. www.gov.uk/childcare-parenting/safeguarding-and-social-care-for-children (last accessed 17/8/2017)
65. Society and College of Radiographers. *Practice standards for the imaging of children and young people*. London: Society and College of Radiographers, 2009.

Recommendation 21

66. Society and College of Radiographers. *Guidance for radiographers providing forensic radiography services*. London: Society and College of Radiographers, 2014.
67. Society and College of Radiographers. *Back to basics: imaging children: guide to radiation protection*. London: Society and College of Radiographers, 2012.
68. The Royal College of Nursing. *Restrictive physical intervention and therapeutic holding for children and young people*. London: The Royal College of Nursing, 2010.
69. Society and College of Radiographers. *Imaging children: immobilisation, distraction techniques and use of sedation*. London: Society and College of Radiographers, 2012.
70. Society and College of Radiographers. *The Ionising Radiations Regulations 1999 (IRR'99): guidance booklet*. London: Society and College of Radiographers, 2012.
71. Society and College of Radiographers. *The child and the law: roles and responsibilities of the radiographer*. London: Society and College of Radiographers, 2005.
72. Hardy M and Boynes S. *Paediatric radiography*. London: Wiley-Blackwell, 2003.
73. Graham P, Hardy M. The immobilisation and restraint of paediatric patients during plain film radiographic examinations. *Radiography* 2004; **10**(1): 23–31.
74. The Royal College of Nursing. *Positive and proactive care: reducing the need for restrictive interventions*. London: The Royal College of Nursing, 2016.

Recommendation 22

75. Society and College of Radiographers. *Imaging children: immobilisation, distraction techniques and use of sedation*. London: Society and College of Radiographers, 2012.

Recommendation 23

76. Society and College of Radiographers. *Imaging children: immobilisation, distraction techniques and use of sedation*. London: Society and College of Radiographers, 2012.

Recommendation 24

77. Society and College of Radiographers. *Use of anatomical side markers*. London: Society and College of Radiographers, 2014.

Recommendation 25

78. Marine MB, Corea D, Steenburg SD *et al*. Is the new ACR-SPR practice guideline for addition of oblique views of the ribs to the skeletal survey for child abuse justified? *AJR Am J Roentgenol* 2014; **202**(4): 868–87.
79. Karmazyn B, Duhn RD, Jennings SG *et al*. Long bone fracture detection in suspected child abuse: contribution of lateral views. *Pediatr Radiol* 2012; **42**(4): 463–469.
80. Karmazyn B, Lewis ME, Jennings SG, Hibbard RA, Hicks RA. The prevalence of uncommon fractures on skeletal surveys performed to evaluate for suspected abuse in 930 children: should practice guidelines change? *AJR Am J Roentgenol* 2011; **197**(1): 159–163.
81. Barber I, Perez-Rossello JM, Wilson CR, Silvera MV, Kleinman PK. Prevalence and relevance of pediatric spinal fractures in suspected child abuse. *Pediatr Radiol* 2013; **43**(11): 1,507–1,515.

- 82. Kleinman PK, Morris NB, Makris J, Moles RL, Kleinman PL. Yield of radiographic skeletal surveys for detection of hand, foot, and spine fractures in suspected child abuse. *AJR Am J Roentgenol* 2013; **200**(3): 641–644.
- 83. Starling SP, Heller RM, Jenny C. Pelvic fractures in infants as a sign of physical abuse. *Child Abuse Negl* 2002; **26**(5):475–480.
- 84. Ingram JD, Connell J, Hay TC, Strain JD, Mackenzie T. Oblique radiographs of the chest in non-accidental trauma. *Emerg Radiol* 2000; **7**(1): 42–46
- 85. Hansen KK, Prince JS, Nixon GW. Oblique chest views as a routine part of skeletal surveys performed for possible physical abuse--is this practice worthwhile? *Child Abuse Negl* 2008; **32**(1): 155–159.
- 86. Barber I, Perez-Rossello JM, Wilson CR, Kleinman PK. The yield of high-detail radiographic skeletal surveys in suspected infant abuse. *Pediatric Radiol* 2015; **45**(1): 69–80.
- 87. Barber I, Perez-Rossello JM, Wilson CR, Silvera MV, Kleinman PK. Prevalence and relevance of pediatric spinal fractures in suspected child abuse. *Pediatric Radiol* 2013; **43**(11): 1,507–1,515.
- 88. Lindberg DM, Harper NS, Laskey AL, Berger RP; ExSTRA Investigators. Prevalence of abusive fractures of the hands, feet, spine, or pelvis on skeletal survey: perhaps “uncommon” is more common than suggested. *Pediatr Emerg Care* 2013; **29**(1): 26–29.

Recommendation 26

- 89. Society and College of Radiographers. *Guidance for radiographers providing forensic radiography services*. London: Society and College of Radiographers, 2014.

Recommendation 29

- 90. General Medical Council. *Domain 3: Communication, partnership and teamwork in Good Medical Practice*. London: General Medical Council, 2013.
- 91. The Royal College of Radiologists. *Standards for the reporting and interpretation of imaging investigations*. London: The Royal College of Radiologists, 2006.

Recommendation 30

- 92. The Royal College of Radiologists. *Standards for the reporting and interpretation of imaging investigations*. London: The Royal College of Radiologists, 2006.
- 93. The Royal College of Radiologists. *Standards for the communication of radiological reports and fail-safe alert notification*. London: The Royal College of Radiologists, 2016.

Recommendation 31

- 94. The Royal College of Radiologists. *Standards for the reporting and interpretation of imaging investigations*. London: The Royal College of Radiologists, 2006.

Recommendation 33

- 95. Singh R, Squires J, Fromkin JB, Berger RP. Assessing the use of follow-up skeletal surveys in children with suspected physical abuse. *J Trauma Acute Care Surg* 2012; **73**(4): 972–976.

96. Bennett BL, Chua MS, Care M, Kachelmeyer A, Mahabee-Gittens M. Retrospective review to determine the utility of follow-up skeletal surveys in child abuse evaluations when the initial skeletal survey is normal. *BMC Res Notes* 2011; **12**(4): 354.
97. Sonik A, Stein-Wexler R, Rogers KK, Coulter KP, Wootton-Gorges SL. Follow-up skeletal surveys for suspected non-accidental trauma: can a more limited survey be performed without compromising diagnostic information? *Child Abuse Negl* 2010; **34**(10): 804–806.
98. Kleinman PK, Nimkin K, Spevak MR *et al.* Follow-up skeletal surveys in suspected child abuse. *AJR Am J Roentgenol* 1996; **167**(4): 893–896.
99. Harlan SR, Nixon W, Campbell K, Hansen K, Prince JS. Follow-up skeletal surveys for non-accidental trauma: can a more limited survey be performed? *Pediatr Radiol* 2009; **39**(9): 962–968.

Recommendation 39

100. Koumellis P, McConachie NS, Jaspan T. Spinal subdural haematomas in children with non-accidental head injury. *Arch Dis Child* 2009; **94**(3): 216–219.
101. Choudhary AK, Bradford RK, Dias MS, Moore GJ, Boal DK. Spinal subdural hemorrhage in abusive head trauma: a retrospective study. *Radiology* 2012; **262**(1): 216–223.
102. Choudhary AK, Ishak R, Zacharia TT, Dias MS. Imaging of spinal injury in abusive head trauma: a retrospective study. *Pediatr Radiol* 2014; **44**(9): 1130–1140. Erratum in: *Pediatr Radiol* 2015; **45**(5): 784.

Recommendation 42

103. National Imaging Board. *Delivering quality imaging services for children*. London: National Imaging Board, 2010.

Recommendation 43

104. Bradford R, Choudhary AK, Dias MS. Serial neuroimaging in infants with abusive head trauma: timing abusive injuries. *J Neurosurg* 2013; **12**(2): 110–119.
105. Vinchon M, Noulé N, Tchofo PJ *et al.* Imaging of head injuries in infants: temporal correlates and forensic implications for the diagnosis of child abuse. *J Neurosurg* 2004; **101**(1 Suppl): 44–52.
106. Adamsbaum C, Morel B, Ducot B, Antoni G, Rey-Salmon C. Dating the abusive head trauma episode and perpetrator statements; key points for imaging. *Paediatr Radiol* 2014; **44**(Suppl 4): s578–s588.s

Recommendation 45

107. Proisy M, Marchand AJ, Loget P *et al.* Whole-body post-mortem computed tomography compared with autopsy in the investigation of unexpected death in infants and children. *Eur Radiol* 2013; **23**(6): 1711–1719.
108. Arthurs OJ, Guy A, Wade A *et al.* Comparison of diagnostic performance for perinatal and paediatric post-mortem imaging: CT versus MRI. *Eur Radiol* 2016; **26**(7): 2,327–2,336.
109. Arthurs OJ, Thayyil S, Addison S *et al.* Diagnostic accuracy of postmortem MRI for musculoskeletal abnormalities in fetuses and children. *Prenat Diagn* 2014; **34**(13): 1,254–1,261.

110. Society and College of Radiographers. *Standards of radiographic practice for post-mortem cross-sectional imaging (PMC-SI)*. London: Society and College of Radiographers, 2015.
111. Baroness Kennedy QC. *Sudden unexpected death in infancy: multi-agency guidelines for care and investigation, second edition*. London: The Royal College of Pathologists and The Royal College of Paediatrics and Child Health, 2016.
112. Garstang J, Ellis C and Sidebotham P. An evidence-based guide to the investigation of sudden unexpected death in infancy. *Forensic Sci Med Pathol* 2015; **11**(3): 345–357.
113. Weber M, Ashworth MT, Risdon R *et al*. The role of post-mortem investigations in determining the cause of sudden unexpected death in infancy. *Arch Dis Child* 2008; **93**(12): 1,048–1,053.

4. Working party members and other contributors

Name	Title/role
Dr Katharine Halliday (Chair)	Consultant Radiologist, Nottingham University Hospital
Dr Geoff Debelles	Officer for Child Protection, the Royal College of Paediatrics and Child Health
Ms Faith Constantine	Lead Paediatric Radiographer, Derriford Hospital, Plymouth, Plymouth and Association of Paediatric Radiographers
Dr Tim Jaspan	Consultant Neuro-Radiologist, Nottingham University Hospital
Ms Sue Johnson	Professional Officer, The Society and College of Radiographers
Ms Christina Freeman	Professional Officer, The Society and College of Radiographers
Dr Katie Giles	Consultant Radiologist, Royal Cornwall Hospital, Truro
Professor Alison Kemp	Professor of Child Health, Cardiff University
Dr Sabine Maguire	Senior Lecturer Child Health, Cardiff University
Dr Amaka C Offiah	Reader in Paediatric Musculoskeletal Imaging and Honorary Consultant Paediatric Radiologist, University of Sheffield
Mrs Katriona O'Hare	RCR lay representative
Dr Ingrid Prosser	Consultant Paediatrician, Brecon Children's Centre
Dr Neil Stoodley	Consultant Neuro-Radiologist, Southmead Hospital, Bristol
Mrs Jackie Vallis	Senior Lecturer Forensic Radiography, Teesside University and International Association of Forensic Radiographers
Mr David Christopher	Professional Standards Manager, The Royal College of Radiologists
Mrs Kim Cyrus	Executive Officer, Clinical Radiology, The Royal College of Radiologists

The College is grateful to Dr Owen Arthurs, National Institute of Health Research Clinician Scientist and Academic Consultant Paediatric Radiologist, Great Ormond Street Hospital, London, and Mr Matthew Dunn, Head of Radiology Physics, Medical Physics and Clinical Engineering, Nottingham University Hospitals NHS Trust, the British Society of Paediatric Radiology (BSPR) and the Society of Forensic Radiographers Patient Representatives for their contributions to this work.

Appendix A.
Skeletal survey:
standard views,
including follow
up, to be obtained**Head, chest, spine and pelvis:**

- Anterior-posterior (AP) and lateral skull
- AP chest (to include the shoulders) and both obliques (obliques to include all ribs, left and right, 1–12)
- AP abdomen and pelvis
- Lateral views to include the whole spine. (For children under one year, this may be possible with one view, for larger children and those over one year, separate views will probably be required.)

Upper limbs:

Where possible:

- AP of the whole arm (centred at the elbow if possible)
- Coned lateral elbow
- Coned lateral wrist
- Posterior-anterior (PA) hand and wrist

In larger children where a single whole arm view is not possible:

- AP humerus (including the shoulder and elbow)
- AP forearm (including the elbow and wrist)
- Coned lateral elbow
- Coned lateral wrist
- DP hand and wrist

• Lower limbs:

Where possible:

- Whole AP lower limb, hip to ankle
- Coned lateral knee and ankle
- Coned AP ankle (mortise view)
- DP foot

For larger children

- AP femur
- AP tibia and fibula
- AP knee
- AP ankle
- Coned lateral knee
- Coned lateral ankle
- DP foot

Follow-up imaging: 11–14 days, no later than 28 days after initial skeletal survey.

- Follow-up radiographs should be performed of any abnormal or suspicious areas on the initial skeletal survey plus the following views:
 - Chest AP and both obliques (to include the shoulders and all ribs, left and right, 1–12)
-

Upper limbs:

Where possible:

- AP whole arm (centred at the elbow if possible)

In larger children where whole arm views are not possible:

- AP humerus (including the shoulder and elbow)
- AP forearm (including the elbow and wrist)

Lower limbs:

Where possible

- Whole AP lower limb, hip to ankle

For larger children:

- AP femur
- AP tibia and fibula

Follow-up imaging should be obtained ideally between 11–14 days after the initial skeletal survey, or as soon as possible thereafter. However, useful information can still be obtained up to 28 days later. If follow-up imaging is not performed within 28 days, the child will need to be reassessed as for an original consultation and full skeletal survey may be required.

Appendix B.

Exemplar information leaflet for those with parental responsibility

Any hospital adopting these guidelines should ensure that they comply with their employer's policies and regulations – and should be endorsed accordingly.	Employing organisation
--	------------------------

This information is for those with parental responsibility for children who need X-rays and scans when there are concerns raised for a child's welfare.

Why are any tests needed in this situation?

NHS hospitals and all their employees have a duty to protect children. Staff are encouraged and expected to raise concerns if they believe the care or welfare of a child is at risk. Although this can be upsetting and difficult for those with parental responsibility, the child's wellbeing and safety comes first.

If any concerns are raised, it is important that these are investigated fully. As part of the investigation it is essential to identify any injuries. In younger children and babies, injuries can be difficult to find. For example, bruising on the surface of the brain can occur without any apparent injury to the outside of the head. Similarly, bones may be broken without any obvious external signs. X-rays and scans can help to diagnose these injuries.

What X-rays and scans will be needed?

A baby or young child will require a skeletal survey X-ray examination and a computed tomography (CT) head scan. Other tests may also be necessary, which could include ultrasound, nuclear medicine or magnetic resonance imaging (MRI) scans.

What is a skeletal survey?

This examination takes place over two visits about two weeks apart. You will be given an appointment for the second visit once the first appointment is complete.

First appointment

The skeletal survey is carried out by appropriately educated and trained paediatric radiographers who are skilled in dealing with children. They will help you and your child throughout the examination. A nurse, or other healthcare professional, will also be present to help and support you and your child.

A skeletal survey is an X-ray examination of the whole body and will involve around twenty separate X-ray images. This can take up to an hour to perform. Your child will need to keep still for each image taken. You may be asked to help hold your child still although toys and other distractions will be available. You may want to bring your child's favourite toy or comforter to help with this. Sometimes your child will be sedated, you will be able to discuss this with your doctor. The staff present will be able to help you in holding your child safely, so as to cause as little distress as possible to both you and your child. You will need to wear a special protective apron while holding your child to prevent your own exposure to X-rays. If you are pregnant, or could be pregnant, you must tell the radiographer. You will not be allowed to hold your child in this case. It is not unusual for a child to become distressed or grizzly during the procedure due to the need to be kept still for the images. You will be able to comfort your child between X-ray images.

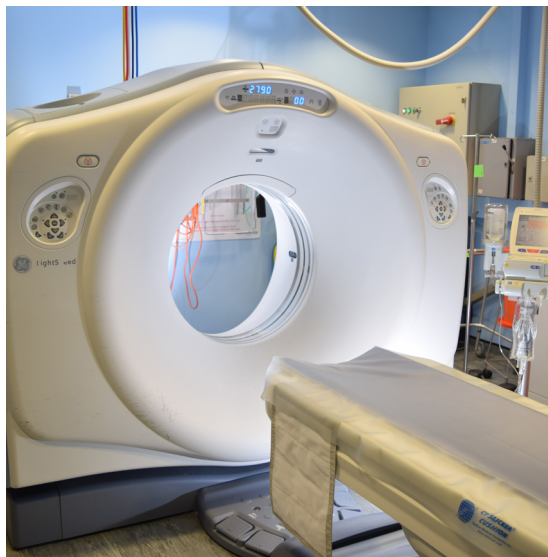
The radiographers who perform the X-rays will not know the result. The images will be reported by a consultant radiologist. The results will be discussed with you by the doctor looking after your child's care.

Second appointment

Sometimes recent injuries are not visible initially and will only be seen on images obtained later. The skeletal survey examination is not complete until a shorter second series of images has been taken. You should ensure your child returns for the second appointment 11–14 days after the first series. You will be given an appointment to bring your child back for these images. The process of taking the images will be very similar to your first appointment.

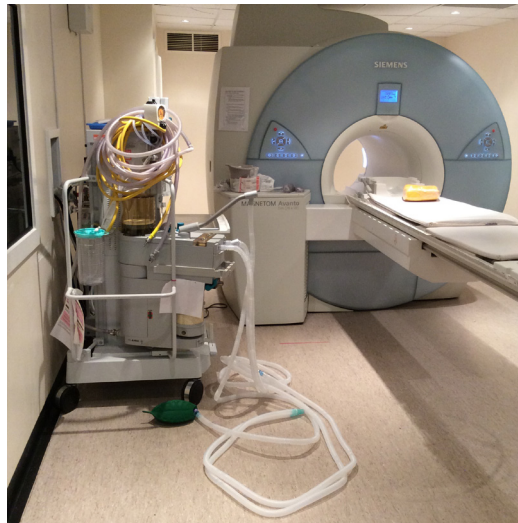CT brain scan

A CT scan is performed by experienced radiographers and produces images of the brain and the skull. The scan is relatively quick although your child will need to lie very still. If you are not pregnant you may be able to stay with your child. Sometimes sedation may be used to help to keep your child still.



The radiographers who perform the CT brain scan will not know the result. The scan will be reported by a consultant radiologist. The results will be discussed with you by the doctor looking after your child's care.

MRI scan



It may be necessary for your child to have a MRI scan of their brain and other areas. This will be performed by experienced radiographers. The MRI scanner looks similar to a CT scanner, but the interior is more like a tunnel. An MRI scan can take up to one hour and is noisy. Your child will need to be perfectly still for this and may need a general anaesthetic. The anaesthetist will explain to you the details of the anaesthetic before your child has the MRI. You will be asked to provide your agreement for this procedure to be undertaken.

The radiographers who perform the MRI scan will not know the result. The scan will be reported by a consultant radiologist. The results will be discussed with you by the doctor looking after your child's care.

Can I stay with my child at all times?

Those with parental responsibility may be able to stay in the room with their child during these examinations. If you are allowed to stay, the radiographer will tell you where to stand/ sit and will ensure that you and your child are safe. Sometimes you may be asked to assist staff in holding your child. The radiographer will help you to do this safely. You do not have to remain in the room if you choose not to, as there will be experienced health staff present to look after your child.

In the X-ray or CT scan room you will be required to wear a heavy protective apron to protect you from the scattered radiation.

If your child is having an ultrasound or MRI scan you do not have to wear any protective clothing.

The MRI radiographers will go through a checklist with you to ensure that it is safe for you and your child to be in close contact to the MRI magnet.

If there is any possibility that you may be pregnant, please tell the radiographer.

Pregnant mother or guardian?

A baby in the womb can be particularly sensitive to the radiation of an X-ray or CT scan.

If you are, or may be, pregnant you can accompany your child to the X-ray department. You may not be allowed in the actual X-ray or scanner room when the X-rays are being used.

A friend or relative may be able to accompany your child if necessary. Professional health staff will always be there to look after your child.

Risks

Radiation

We are all exposed to natural background radiation. This is made up of cosmic rays, radon; from some foods and from the ground.

Every X-ray gives us a small additional dose of radiation.

A skeletal survey is equivalent to a few months' background radiation.

A CT head scan is equivalent to about 18 months' background radiation.

These extra exposures to radiation slightly increase the lifetime cancer risk but the increase in risk is very small.

Your child will not be exposed to any more X-rays and scans than is absolutely necessary to adequately complete the examinations. Before any examination that uses radiation is carried out, the benefits of having the examination are closely weighed against the risks of the radiation itself.

All X-ray doses are kept 'as low as reasonably practicable' to ensure that images of a high diagnostic quality are obtained without exceeding accepted doses. This is particularly the case with children as they are still growing and more susceptible to radiation. The radiographers will use techniques to try to ensure that they achieve the correct X-ray first time and use various methods to keep the dose to your child as minimal as possible. Your child will not be exposed to any more radiation than needed to gain the examinations required

For further information:

NHS Choices – Radiation www.nhs.uk/conditions/Radiation/Pages/Introduction.aspx

GOV UK – Radiation: risks from low levels of ionising radiation. 2008

www.gov.uk/government/collections/radiation-risks-from-low-levels-of-ionising-radiation

You can also seek further information from your radiographer.

MRI

Extensive research has been carried out into whether the magnetic fields and radio waves used during MRI scans could pose a risk to the human body. No evidence has been found to suggest there's a risk, which means MRI scans are one of the safest medical procedures currently available.

Not everyone can have an MRI scan. For example, they're not always possible for people who have certain types of metal implants fitted, such as a pacemaker (www.nhs.uk/conditions/pacemakerimplantation/pages/introduction.aspx) (a battery-operated device that helps to control an irregular heartbeat [www.nhs.uk/conditions/Heart-palpitations/Pages/Introduction.aspx]). A safety check will be done by the radiographer for you and your child before an MRI scan.

Appendix C.
Exemplar
consent form

Any hospital adopting these guidelines should ensure that they comply with their employer's policies and regulations – and should be endorsed accordingly.

Employing organisation

Patient identifier detail/label

Name: _____

Date of birth: _____

NHS number: _____

Male/female: _____

Sections 1 and 2 to be completed by the referring doctor**1. Details of proposed radiological investigations**

I have explained the procedure to the person with parental responsibility for the child, or accompanying member of staff if that individual is attending with the child, including:

- When and where the examination will take place (if known)
- Who will be present and who will take the images
- Requirement for child to be kept still and possible methods
- Nature of images to be acquired, for example, head CT scan, X-ray images etc.
- Need for follow-up imaging
- Process and timescale for results
- Possible further radiological examinations etc.
- Provided the advice leaflet
- Additional information:

The reasons for the radiological investigation(s):

Any risks associated with the investigation(s):

Signature of referring doctor:

Date:

Name (print):

Job Title:

2. Where applicable: Details of any court order supporting this examination, for example, Emergency Protection Order or equivalent

• Court order number:

• Additional information, for example, date of expiry:

TO BE COMPLETED BY THE INTERPRETER (IF PRESENT):

3. I have, to the best of my ability; accurately communicated the information provided by the doctor to the person with parental responsibility and relayed any queries back to the doctor.

Signed:

Date:

Name (print):

Special requirements

4. The communication and access needs of the person with parental responsibility have been met, for example, language interpretation, sign language, access needs etc. (circle which is appropriate)

- No specific needs identified
- Yes

If yes please state what was provided:

To be completed by the person with parental responsibility/legal guardian

5. To be completed by the person with parental responsibility:

- I confirm that I have legal responsibility for this child.
- I agree to the radiological investigation(s) described on this form being performed on my child.
- I confirm I have had the opportunity to have any questions about the procedure answered.
- Should sedation or general anaesthetic be required I understand that I will have the opportunity to discuss the details with the paediatrician or anaesthetist. I understand an additional consent form will be required.

Signature:

Date:

Name (print):

Relationship to child:

Section 6 and 7 to be completed by lead radiographer on admitting child to imaging room for procedure

6. Confirmation of agreement

I have:

- Confirmed the identity of the child with the person with parental responsibility
- Checked that they have no further questions

- Checked prior documentation of consent
- Ensured that they give permission for the radiological examination(s) including any required immobilisation to go ahead.

Signed: _____ Date: _____

Name(print):. _____ Job title: _____

7. If the person with parental responsibility withdraws consent at any time during procedure, signature is required below, along with the reason for withdrawal.

Reason: _____

Signed (person with parental responsibility): _____

Date: _____ Time: _____

Signed (radiographer): _____

Date: _____ Time: _____

Appendix D.

Exemplar skeletal survey competency form

Any hospital adopting these guidelines should ensure that they comply with their employer's policies and regulations – and should be endorsed accordingly.	Employing organisation
--	------------------------

Suspected physical abuse skeletal surveys are challenging for radiographers due to a number of reasons including:

- Suspected safeguarding issues
- Distressed child and, if present, person with parental responsibility
- Length of procedure
- Comforting/holding required.

Any radiographer considering training in this procedure should carefully consider the above.

Rationale:

It is the expectation of the Society and College of Radiographers (SCoR) that all radiographers registered with the Health and Care Professions Council are competent to carry out imaging procedures on children of all ages from birth to adulthood. Postgraduate education and training in paediatric and forensic imaging must be undertaken by any radiographer who might be required to undertake imaging in relation to examinations which are complex and which may involve forensic and legal elements. www.sor.org/learning/document-library/practice-standards-imaging-children-and-young-people/5-standard-requirements

Further information on the knowledge, education and skills required specifically for the imaging of suspected physical abuse are to be found in the Guidance For Radiographers Providing Forensic Radiography Services. www.sor.org/learning/document-library/guidance-radiographers-providing-forensic-radiography-services-0

The SCoR have many other resources' links and guidance documents available for radiographers involved in the radiographic examination of children. www.sor.org/practice/hot-topics/children

Both the SCoR and The Royal College of Radiologists have produced guidance specifically for suspected physical abuse Skeletal Survey.

www.sor.org/learning/document-library/skeletal-survey-suspected-nai-sids-and-sudi-guidance-radiographers

For this organisation, a competency framework has been developed for those radiographers involved in the imaging of suspected physical abuse. The lead paediatric radiographer must be satisfied that the learner has read and understood these documents and identified and addressed any further educational needs. Practical experience, training, assessment and sign-off of competency in paediatric imaging are required prior to being assessed as competent for suspected physical abuse.

Pre-procedure knowledge [NB: A similar form should be used for each element of imaging.

The learner shows an understanding of	Assessors name, signature initials and date
Paediatric imaging and its difference to the imaging of adults. Their current level of training and competence in imaging children	
Indications for imaging	
Consent for suspected physical abuse including responsibilities to obtain	
Radiographic standards and principles, to include exposure factors and diagnostic reference levels (DRLs), and equipment to be used. Demonstrates competence in managing/communicating with children, acquiring required range of images, assessing images and optimising doses	
The role and responsibilities of the radiographers including the legal framework of forensic imaging.	
Compare and contrast between different age groups with regard to communication, immobilisation and consent	
The purpose of follow-up images	
Appreciate the role of other imaging techniques.	
The use of a system of work for suspected physical abuse (See following pages) (See following pages)	
Date of assessment of competence:	
Name and signature of assessor:	
Name and signature of radiographer assessed:	
Comments:	

On receipt of requests		Initial assessment	Final assessment
	Tick	Date	Date
Check request contains:			
E-request on maxims			
Ensure discussed and approved by consultant radiologist			
States suspected physical abuse and any current clinical problems and relevant past history			
Informs the shift coordinator and team leader or advanced practitioner in their absence			
Inform directorate office			
Arranging survey			
Check that a paediatric radiologist is available to view images – or if unavailable another consultant radiologist is available to view			
Co-ordinate examination with CT for CT head			
Ensure two adequately trained radiographers and a suitable room are available			
Liaise with ward			
Check when pain relief, sedation, feeds or sleep will be, to arrange suitable time for when patient is most comfortable.			
Check a registered nurse is available to escort and remain with the patient for the entire procedure.			
Check the person with parental responsibility's consent is documented (on consent form or in the notes)			
Check if a person with parental responsibility will be accompanying the patient YES/ NO			
Notes are requested from the ward			
Supervising radiographer who is suspected physical abuse competent (initials)			
Comments			

When patient is in department	Initial assessment	Final assessment
	Date	Date
Ensure appropriate imaging colleagues are aware of suspected physical abuse procedure and that radiographers cannot be disturbed		
Check the patient is booked in correctly – X-ray skeletal survey non-accidental injury (XSSNA)		
Check notes have arrived		
Gather equipment, including departmental markers, and ensure the room is prepared with lead screen if required		
If the person with parental responsibility is accompanying, be clear they will not be able to stand at the control panel Supply lead apron or lead screen for the person with parental responsibility		
Conduct a briefing		
<ul style="list-style-type: none"> ▪ The procedure should be discussed with the team including nurse to ensure roles are clear. 		
<ul style="list-style-type: none"> ▪ Ensure both radiographers are aware they are responsible for all aspects of the examination including patient ID. 		
<ul style="list-style-type: none"> ▪ Ensure that a radiographer is present in the room throughout the entire examination until the patient leaves the department. 		
Check ALL clothing removed from area of interest, including nappy. If the room is very cold try warming a pillow case or draw sheet first to put baby on whilst X-raying.		
Ensure identity wristband will not be projected over ankle or wrist joint or remove wristband		
Complete examination as per age group		
Ensure metal side markers are visible on each view and do not obscure any part of the anatomy.		
Ensure both radiographers have checked each image for exposure factors before acquiring image.		
Ensure both radiographers review images for quality, positioning and exposure factors/dose–area product (DAP) and initial on each view		

When patient is in department	Initial assessment	Final assessment
Images should be checked by the consultant radiologist before the child has left the room.		
Following examination		
Ensure all sections of suspected physical abuse checklist are fully completed		
Scan the checklist onto computerised radiology information system (CRIS)		
Hand this sheet to the team leader for checking		

Appendix E.

Exemplar initial skeletal survey check form

Any hospital adopting these guidelines should ensure that they comply with their employer's policies and regulations – and should be endorsed accordingly.

Employing organisation

The lead radiographer is responsible for ensuring this form is completed.

Name of child:

Hospital/NHS numbers/identifier

Name of holder 1:

Status:

Name of holder 2:

Status:

Name of radiographer 1 (lead):

Name of radiographer 2:

Name of any other person(s) present and their status:

Person with parental responsibility's consent form seen and all sections completed:

Yes/No

If 'No' seek advice from referring clinician.

Brief description of child undergoing examination: (for example, asleep, crying, restless etc):

Signature of lead radiographer 1:

Date for follow-up films(11–14 days after)

Signature of radiographer 2:

Attended?

Name of radiologist checking images:

Consultant paediatrician and consultant paediatric radiologists informed of attendance?

Name of radiologist reporting images:

Yes/No

If 'no' please state what action has been taken.

This form details the imaging techniques to be used as well as providing a record of the examination. The form should be stored locally and/or scanned against the imaging record on the radiology management system.

A record of all image factors should be kept including repeats.

Where possible a single image may be taken of a whole limb or lateral spine, however, in larger children, separate images of each area should be obtained as indicated on the form below.

Images required		Kilovoltage peak (kvp)	Milliampere-seconds (mAs)	DAP	Annotations post processing	Radiographer check (image quality, PACS)
All children						
Small child	Large child					
Anterior-posterior (AP) skull						
Lateral skull						
AP chest (to include shoulders)						
Right oblique chest (show both sides, ribs 1–12)						
Left oblique chest (show both sides, ribs 1–12)						
AP abdomen and pelvis						
Lateral whole spine	Lateral cervical and thoracic spine					
	Lateral lumbar spine					
AP whole right arm (centre at elbow)	AP right humerus (shoulder to elbow)					
	AP right forearm (elbow to wrist)					
Coned right lateral elbow						
Coned right lateral wrist						
DP right hand and wrist						
AP whole left arm (centre at elbow)	AP left humerus (shoulder to elbow)					

Images required		Kilovoltage peak (kvp)	Milliampere-seconds (mAs)	DAP	Annotations post processing	Radiographer check (image quality, PACS)
All children						
Small child	Large child					
	AP left forearm (elbow to wrist)					
Coned left lateral elbow						
Coned left lateral wrist						
DP left hand and wrist						
Whole AP right lower limb, hip to ankle	AP right femur (hip to knee)					
	AP right tibia and fibia (knee to ankle)					
	AP right knee					
	AP right ankle					
Coned AP right ankle (mortise view)						
Lateral right knee						
Lateral right ankle						
DP right foot						
Whole AP left lower limb, hip to ankle	AP left femur (hip to knee)					
	AP left tibia and fibia (knee to ankle)					
	AP left knee					
	AP left ankle					
Coned AP left ankle (mortise view)						
Lateral left knee						
Lateral left ankle						
DP left foot						

Image	kVp	mAs	Dap reading	Held by:	Annotated post processing	Radiographer Image check
AP skull						
Lateral skull						
AP chest						
Oblique chest 1						
Oblique chest 2						
AP abdomen and pelvis						
Lateral whole spine						
Lateral whole spine						
AP right whole arm (or separate humerus)						
AP right whole arm (or separate forearm)						
AP left whole arm (or separate humerus)						
AP left whole arm (or separate forearm)						
Lateral right elbow						
Lateral left elbow						
Lateral right wrist						
Lateral left wrist						
DP right hand and wrist						
DP left hand and wrist						
AP whole right lower limb (or separate femur)						
AP whole right lower limb (or separate tibia/fibia)						
AP whole left lower limb (or separate femur)						
AP whole left lower limb (or separate tibia/fibia)						

Image	kVp	mAs	Dap reading	Held by:	Annotated post processing	Radiographer Image check
AP whole right lower limb (or separate femur)						
AP whole right lower limb (or separate tibia/fibia)						

Appendix F.

Alternative forms of skeletal imaging

1. Radioisotope bone scanning

There is currently insufficient evidence that performing an initial bone scan and skeletal survey will obviate the need for further imaging. A bone scan can highlight areas of suspicion, but further imaging is necessary to confirm whether or not there are any fractures. In addition, bone scanning cannot help with the dating of injuries and this procedure involves a high radiation dose. Bone imaging is therefore not usually indicated.

References:

1. Mandelstam SA, Cook D, Fitzgerald M, Ditchfield MR. Complementary use of radiological skeletal survey and bone scintigraphy in detection of bony injuries in suspected child abuse. *Arch Dis Child* 2003; **88**(5): 387–390.
2. Jaudes PK. Comparison of radiography and radionuclide bone scanning in the detection of child abuse. *Pediatrics* 1984; **73**(2): 166–168.
3. Conway JJ, Collins M, Tanz RR *et al*. The role of bone scintigraphy in detecting child abuse. *Semin Nucl Med* 1993; **23**(4): 321–333.

2. Computed tomography (CT)

CT has been shown to be more sensitive in the diagnosis of rib fractures than traditional radiography. Although the increased radiation dose does not currently justify its routine use, it can be an invaluable adjunct in cases of diagnostic uncertainty. As low-dose techniques are developed, CT will have a greater role to play in the diagnosis of rib fractures. There is no concern regarding radiation dose in the post mortem-setting and thus post-mortem CT may be useful to further evaluate skeletal trauma

References:

1. Wootton-Gorges SL, Stein-Wexler R, Walton JW *et al*. Comparison of computed tomography and chest radiography in the detection of rib fractures in abused infants. *Child Abuse Negl* 2008; **32**(6): 659–663.
2. Hong TS, Reyes JA, Moineddin R *et al*. Value of postmortem thoracic CT over radiography in imaging of pediatric rib fractures. *Pediatr Radiol* 2011; **41**(6): 736–748.
3. Sanchez TR, Lee JS, Coulter KP, Seibert JA, Stein-Wexler R. CT of the chest in suspected child abuse using submillisievert radiation dose. *Pediatr Radiol* 2015; **45**(7): 1,072–1,076.
4. Sanchez TR, Grasparil AD, Chaudhari R, Coulter KP, Wootton-Gorges SL. Characteristics of Rib Fractures in Child Abuse-The Role of Low-Dose Chest Computed Tomography. *Pediatr Emerg Care* 2016 Jan 12. [Epub ahead of print].

3. Ultrasound

Ultrasound may be useful in the diagnosis of sub periosteal fluid, metaphyseal and rib fractures.

References:

5. Markowitz RI, Hubbard AM, Harty MP *et al*. Sonography of the knee in normal and abused infants. *Pediatr Radiol* 1993; **23**(4): 264–267.
6. Kelloff J, Hulett R, Spivey M. Acute rib fracture diagnosis in an infant by US: a matter of child protection. *Pediatr Radiol* 2009; **39**(1): 70–72.

4. Magnetic resonance imaging (MRI)

MRI has an increased sensitivity for soft-tissue injuries and can be helpful in selected cases. Whole-body MRI has not yet been shown to be of routine value.

Reference:

1. Perez-Rossello JM, Connolly SA, Newton AW, Zou KH, Kleinman PK. Whole-body MRI in suspected infant abuse. *AJR Am J Roentgenol* 2010; **195**(3): 744–750.

Appendix G.

Exemplar follow-up imaging form for those with parental responsibility

Any hospital adopting these guidelines should ensure that they comply with their employer's policies and regulations – and should be endorsed accordingly.

Employing organisation

Organisation logo (including contact numbers of imaging and paediatric X-ray)

Second visit

Follow-up imaging for unexplained injuries.

To be given to the person with parental responsibility

This appointment is logged on to the hospital's booking system to ensure that in the event of your child not attending, an alert is produced.

Follow-up imaging

Follow-up X-ray imaging, between 11–14 days after the primary survey, is always required for children that have undergone X-rays for skeletal surveys. Other follow-up imaging may also be required.

An appointment is needed for these examinations.

Please ensure that:

Name:

DOB:

NHS number:

Attends for further imaging (specify):

On:

Time:

Place:

Contact details of hospital department:

Contact name(s):

Follow-up imaging is an essential part of the original skeletal survey, and a complete report cannot be given until these images have been taken.

Please contact the hospital if there are any problems with attending this appointment.

Failure to attend this appointment will result in action being taken to ensure that your child has the follow-up imaging required.

Appendix H.

Exemplar follow-up imaging form for those with parental responsibility

Any hospital adopting these guidelines should ensure that they comply with their employer's policies and regulations – and should be endorsed accordingly.

Employing organisation

Name of child:

Hospital/NHS numbers/identifier:

Name of holder 1:

Status:

Name of holder 2:

Status:

Name of radiographer 1 (lead):

Name of radiographer 2 :

Name of any other person(s) present and their status:

Person with parental responsibility's consent form seen and all sections completed: Yes/No

If 'No' seek advice from referring clinician.

Brief description of child undergoing examination: (for example, asleep, crying, restless etc).

Signature of lead radiographer 1:

Date for follow up films(11–14 days after):

Signature of radiographer 2:

Attended?

Date:

Consultant paediatrician and consultant paediatric radiologists informed of attendance? Yes/No

Name of radiologist checking images:

If 'no' please state what action has been taken:

Name of radiologist reporting images:

This form details the imaging techniques to be used as well as providing a record of the examination. The form should be stored locally and/or scanned against the imaging record on the radiology management system.

A record of all image factors should be kept, including repeats.

Where possible, a single image may be taken of a whole limb or lateral spine, however, in larger children, separate images of each area should be obtained as indicated on the form below.

Images required		Kilovoltage peak (Kvp)	Milliamperage-seconds (mAs)	Dose-area product (DAP)	Annotations post processing	Radiographer check (image quality, PACS)
All children						
Small child	Large child					
Anterior-posterior (AP) chest (to include shoulders)						
Right oblique chest (show both sides, ribs 1–12)						
Left oblique chest (show both sides, ribs 1–12)						
AP whole right arm (centre at elbow)	AP right humerus (shoulder to elbow)					
	AP right forearm (elbow to wrist)					
Coned right lateral elbow						
Coned right lateral wrist						
DP right hand and wrist						

Images required		Kilovoltage peak (Kvp)	Milliamperage- seconds (mAs)	Dose-area product (DAP)	Annotations post processing	Radiographer check (image quality, PACS)
AP whole left arm centre at elbow)	AP left humerus (shoulder to elbow)					
	AP left forearm (elbow to wrist)					
Whole AP right lower limb, hip to ankle	AP right femur (hip to knee)					
	AP right tibia and fibia (knee to ankle)					
Whole AP left lower limb, hip to ankle	AP left femur (hip to knee)					
	AP left tibia and fibia (knee to ankle)					
Images as required from previous survey report (detail below)						

Appendix I.

Exemplar standard operating procedure for follow-up imaging

Any hospital adopting these guidelines should ensure that they comply with their employer's policies and regulations – and should be endorsed accordingly.	Employing organisation
--	------------------------

Unexplained injuries in paediatrics: procedure to ensure patient attends for follow-up imaging

Date	Version

Purpose

The purpose of this document is to ensure that patients attend imaging departments for follow-up imaging that is required as part of an original traditional radiographic skeletal survey.

Who should read this document?

Imaging staff with responsibility for paediatrics – radiologists, radiographers, clerical staff.

Paediatric staff involved with cases that require skeletal surveys – paediatricians, general practitioners (GP's), paediatric nursing staff, paediatric clerical staff.

Safeguarding Children Team.

Paediatric social care.

Key messages

To ensure that those responsible for the child understand that follow-up images are required as part of the complete skeletal survey. A robust system should be put in place to ensure that the child returns for this imaging on a set date and time. This is especially important, as those with parental responsibility with the child for the primary skeletal survey may not be looking after the child after discussions regarding the safe placement of the child.

Accountabilities	
Production	
Review and approval	
Ratification	
Dissemination	
Compliance	

Links to other policies and procedures

Protocol for traditional radiographic skeletal survey for suspected physical abuse in children.

Protocol for CT imaging in cases of suspected physical abuse in children.

Version history

Last approval	Due for review

Standard operating procedures are designed to promote consistency in delivery, to the required quality standards, across the organisation. They should be regarded as a key element of the training provision for staff to help them to deliver their roles and responsibilities.

Section	Description	Page
1	Purpose and scope	
2	Definitions	
3	Regulatory background	
4	Key duties	
5	Monitoring and assurance	
6	Procedure to follow	
7	Main step 1	
8	Main step 2 etc	
9	Document ratification process	
10	Dissemination and implementation	
11	Reference material	
	Appendices	
	Required documentation (example)	
	Electronic processes and records (example)	
	Specialised processes (example)	

Exemplar standard operating procedure (SOP): Unexplained injuries in paediatrics: procedure to ensure patient attends for follow-up imaging

1. Purpose and scope

Introduction

Imaging of children is usually required when other identified injuries (for example, bruising) are unexplained. Due to the nature of some fractures, they are not always visible on early presentation. A primary radiographic skeletal survey is undertaken on presentation.

It is recognised that subsequent images, after a set time interval, may help to reveal fractures not seen on the primary survey.

This paediatric group is normally limited to children under two years old – but it may include older children.

Definitions

Traditional radiographic skeletal survey – imaging of specific areas of a child's body using X-rays.

Background guidance

The Royal College of Radiologists. *The radiological investigation of suspected physical abuse in children*. London: The Royal College of Radiologists, 2017.

Key duties

Consultant paediatric radiologists, or other consultant radiologists recognised to undertake the role of reporting images for suspected abuse, should ensure that the report of the preliminary findings includes requirements for follow-up imaging and the time interval. This interval should normally be set in the 'standard operating procedure for identifying unexplained injuries in paediatrics.' Staff performing the primary survey will make those with parental responsibility aware of this procedure.

Consultant paediatricians and other medical staff involved should also be aware of this procedure so that when discussing the findings of the primary survey they are able to inform those with parental responsibility that the final report will not be issued until the follow-up imaging has been performed.

Monitoring and assurance

A robust system should be put in place to ensure that a child is brought in for this follow-up imaging, and who should act if the child does not attend. An appointment should be provided during normal working hours.

Initial discussion involving all parties should decide which department should monitor this. It makes sense for imaging services to do this via their booking system. The appointment should be put on the system at the time of the primary survey and those with parental responsibility provided with a written appointment sheet. It is prudent to inform the consultant radiologist and paediatric radiographers.

The imaging service should have in place a policy for those patients that do not attend for bookings. An alert should be attached to this booking so that non-attendance is immediately flagged.

If a child is not brought in for the appointment then clerical staff should bring this fact to the attention of both the reporter of the primary survey and the paediatric radiographers. Clerical staff should be trained to understand the importance of this communication. It is good practice for the lead paediatric radiographer to be involved in this chain, and to act as a second line of monitoring any shortfalls.

On being alerted to the missed appointment an escalation plan should be implemented. This should detail any process to determine why the child was not brought in. A clear chain of responsibility should be described. This should involve the assistance of the safeguarding children team, children's social carer and the child's consultant paediatrician. The reason for non-attendance should be ascertained and the carers should then be advised to bring the child in for further imaging within a suitable time frame (follow-up imaging is still of value up to 28 days after the initial survey), within normal working hours.

Refusal to attend or inability to make contact must be discussed with the referring paediatric consultant in case legal action is required. If this is the outcome, then the responsibility now lies with the original paediatric consultant and the safeguarding team.

Responsibility for monitoring these results lies with the imaging department, and ultimately with the consultant radiologist reporting the primary survey. A robust working relationship between all parties should be maintained with clear and open communication channels.

There may be occasions when follow-up imaging is performed at another centre. Where this is the case then all parties involved in facilitating the original survey should be aware. It is also important that the other centre knows what specific images are to be performed and who is going to report them. This will involve radiologists and radiographers at both centres.

A record should be kept of skeletal surveys performed by the imaging department. The information should be audited to:

- Aid in making improvements to the system, for example, in relation to:
 - Staff training
 - Staff availability
 - Timescales
 - Communication
 - Image quality
- Monitor activity in this specific paediatric area
- Compare with national data
- Demonstrate any trends.

2. Procedure to follow

This section should be completed by individual organisations

Main step 1

Summary of step

Main step 2

Summary of step

Wherever possible, or relevant, support this narrative with a range of:

- Process and decision flow charts, which reflect the key duties
- Functions and responsibilities tables
- Monitoring and quality assurance arrangements.

3. Document ratification process

This section should be completed by individual organisations.

4. Reference material

The Royal College of Radiologists. *The radiological investigation of suspected physical abuse in children*. London: The Royal College of Radiologists, 2017.

Plus any individual organisation guidelines.

Appendix 1

Appendices should be specifically referred to in the body of the procedural note and included within the contents page.

Required documentation

Include copies of each form that is needed to be completed as part of the procedure described. If this is not practical or appropriate, then clearly indicate where the reader may locate the relevant forms. Aim to standardise forms used across the organisation. Where this is not possible, aim for partial standardisation, with specific additional sections to reflect differences across specialties and functions.

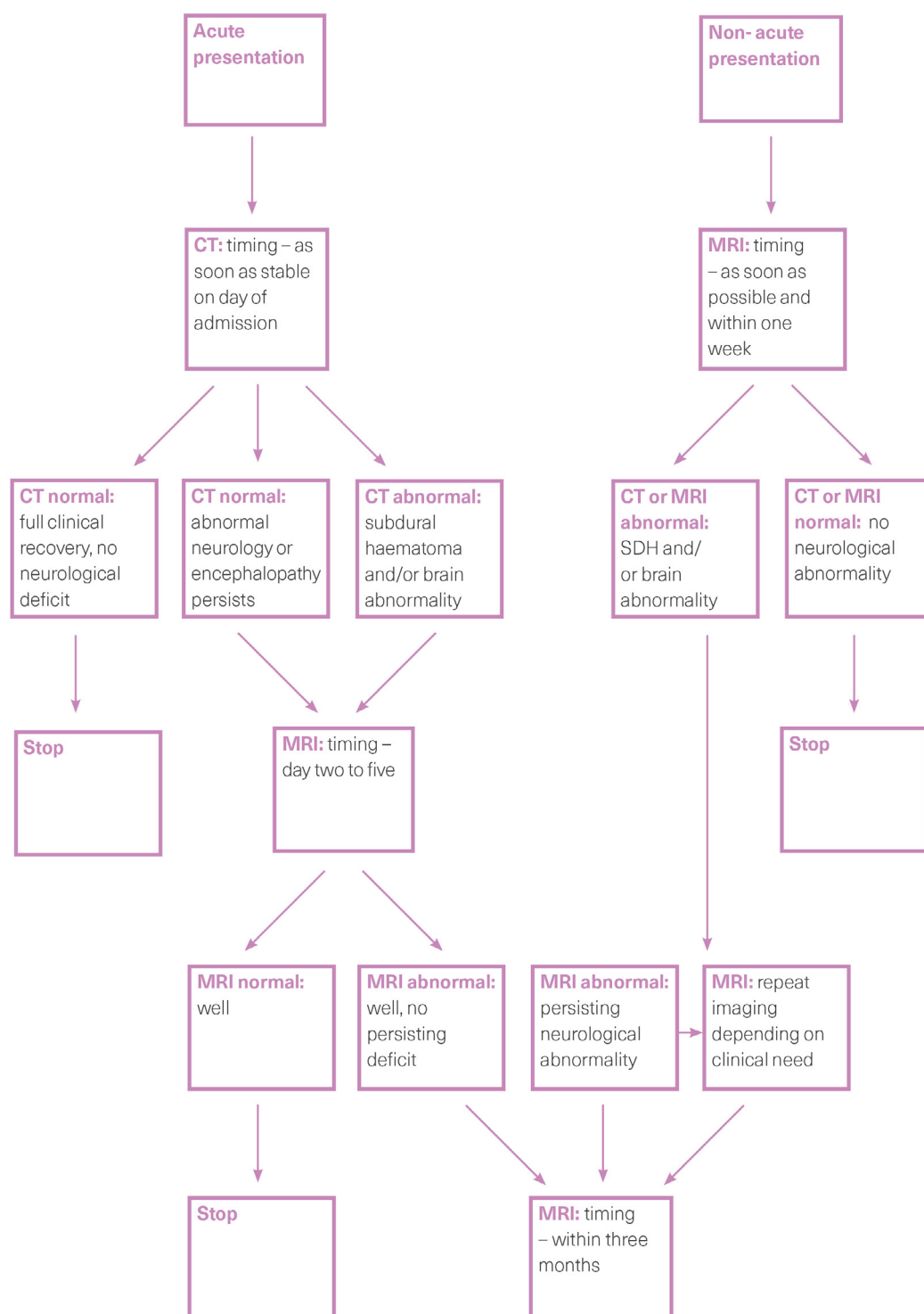
Electronic processes and records

Include brief descriptions, supplemented with (for example) screen prints, key function flowcharts, system menus and so on, with links to electronic guidance for each of the key software packages used as part of the procedure.

Specialised processes

Include further detailed steps for processes, where it makes sense to include within the main procedural document, that is, where the majority of the procedure is the same as the standard approach, but with specific and significant differences at certain stages of the procedure.

Appendix J. Neuro imaging algorithm for suspected physical abuse



Appendix K. MRI protocols

Brain:

- Sagittal and axial T1
- Axial T2
- Axial or coronal fluid-attenuated inversion recovery (FLAIR)
- Axial T2 gradient echo or susceptibility-weighted imaging (SWI)/diffusion-weighted imaging (DWI)

Spine:

- Sagittal T1, T2, short T1 inversion recovery (STIR)
 - Axial T1 and T2 imaging as required.
-

Appendix L. Audit proforma

Example questions to include in an audit:

1. How many skeletal surveys were performed in the study period?
2. How many were in children 0–5 months, 6–11 months, 12–24 months, >1 year?
3. How many in each group had cranial imaging?
4. How soon after the request was cranial imaging performed?
5. How soon after the request was skeletal imaging performed?
6. Were those with parental responsibility given an explanatory leaflet?
7. Was written consent obtained?
8. Was consent verbally reaffirmed by radiographers when the patient arrived in the department?
9. Was the skeletal survey performed by two radiographers with documented education and training in paediatric radiography forensic techniques?
10. Was a paediatric nurse or registered healthcare practitioner also present during the examination?
11. Was the child sedated for cranial imaging?
12. Was the child sedated for skeletal survey?
13. If the child was not sedated, were appropriate toys or distraction equipment available during the examination?
14. What immobilisation techniques were used?
15. Who held the child during the procedure?
16. Were anatomical side markers present in the primary beam on all appropriate images? If not, in how many were they present and how many absent?
17. Was the complete set of views obtained (see Appendix A)? If not which projections were not obtained and why not?
18. Was initial cranial imaging computed tomography (CT) or magnetic resonance imaging (MRI) undertaken?
19. Please document all cranial imaging performed and the clinical indications.
20. Please document all spinal imaging performed and the clinical indications.
21. Was additional body imaging performed? (for example, body CT, ultrasound, scintigraph).
22. Was appropriate documentation and contemporaneous records completed by the radiographers?
23. Was the survey reviewed by a radiologist within 24 hours? If not, why not? If so, were extra views requested/performed?
24. How soon after completion of the study was the imaging (cranial and skeletal) reported?
25. Was a consensus report produced by two consultant radiologists, each with at least six months of specialist paediatric radiology training for both cranial and skeletal imaging?
26. Were multiplanar reconstructions made available at the time of reporting?
27. How many patients returned for follow-up imaging?

The Royal College of Radiologists
63 Lincoln's Inn Fields
London WC2A 3JW

+44 (0)20 7405 1282

enquiries@rcr.ac.uk

www.rcr.ac.uk

[@RCRadiologists](https://twitter.com/RCRadiologists)

Endorsed by the Royal College
of Paediatrics and Child Health

